

# Development of an Artificial Intelligence Model for the Evaluation of Histopathologic Features of Eosinophilic Esophagitis

Luisa Ricaurte Archila, Donnchadh O'Sullivan, Maria Camila Cardenas-Fernandez, Lindsey Smith, Hanna-Kaisa Sihvo, Thomas Westerling, Karthik Ravi, Crystal Lavey, Taofic Mounajjed, Christopher Hartley, Rish Pai, Rondell P. Graham, Puanani Hopson, Imad Absah, Roger K. Moreira.



## BACKGROUND

The clinical-pathologic diagnosis of eosinophilic esophagitis (EoE) currently requires >15 eosinophils per HPF. Peak eosinophil count is the most reported histopathologic parameter. The eosinophilic esophagitis histologic scoring system (EoEHSS) is a semiquantitative method that has recently been developed and validated. However, this method is semi-quantitative, work-intensive, and relatively difficult to implement in practice.

In an attempt to provide automated, quantitative, reproducible, and standardized histologic analyses in cases of EoE, we have developed an artificial intelligence (AI)-based digital pathology model for the evaluation of histologic features in the spectrum of EoE/esophageal eosinophilia (Fig 1). Here, we describe the development and validation of this novel AI tool.

## DESIGN

\* 10,726 objects and 56.2 mm<sup>2</sup> of semantic segmentation areas were annotated on whole-slide images, utilizing a cloud-based, deep learning artificial intelligence platform (Aiforia Technologies, Helsinki, Finland).

\* Our training set consisted of 40 carefully selected digitized esophageal biopsy slides which contained the full spectrum of changes typically seen in the setting of esophageal eosinophilia, ranging from normal mucosa to severe abnormalities.

\* A subset of cases was reserved as independent 'test sets' in order to assess the validity of the AI model outside the training set.

\* Five specialized experienced gastrointestinal pathologists scored each feature blindly and independently for validation. The performance of the AI model was compared to that of the GI pathologists (Tables 1 and 2).

## RESULTS

**Table 1. Accuracy of AI model for segmentation features**

Segmentation feature	Accuracy
Tissue	1.01
Spongiosis	1.15
Basal layer	1.05
Surface layer	1.04
Lamina propria	1.15
Collagen	1.11
Degranulation	2.23

1. "perfect or nearly perfect" (95-100%, no significant errors)
2. "very good" (80-95%, only minor errors)
3. "good" (70-80%, significant errors but still captures the feature well)
4. "insufficient" (less than 70%, significant errors compromising feature recognition).

**Table 2. Performance of AI model for all cell types**

	Eosinophils		Lymphocytes		Squamous cells	
	AI vs Human	Human vs Human	AI vs Human	Human vs Human	AI vs Human	Human vs Human
<b>Sensitivity%</b>	95.2	96.3	94.3	92.7	93.2	95.2
<b>Specificity%</b>	94.2	95.7	93.0	90.3	96.7	94.1
<b>FP%</b>	5.8	4.3	7.0	9.7	3.3	5.9
<b>FN%</b>	4.7	3.6	5.6	7.2	6.7	4.7
<b>Error %</b>	9.0	6.8	10.1	13.2	9.5	9.5
<b>Precision%</b>	95.2	96.3	94.5	92.7	96.8	94.9
<b>F1-score %</b>	94.8	96.0	94.5	92.6	94.7	94.7

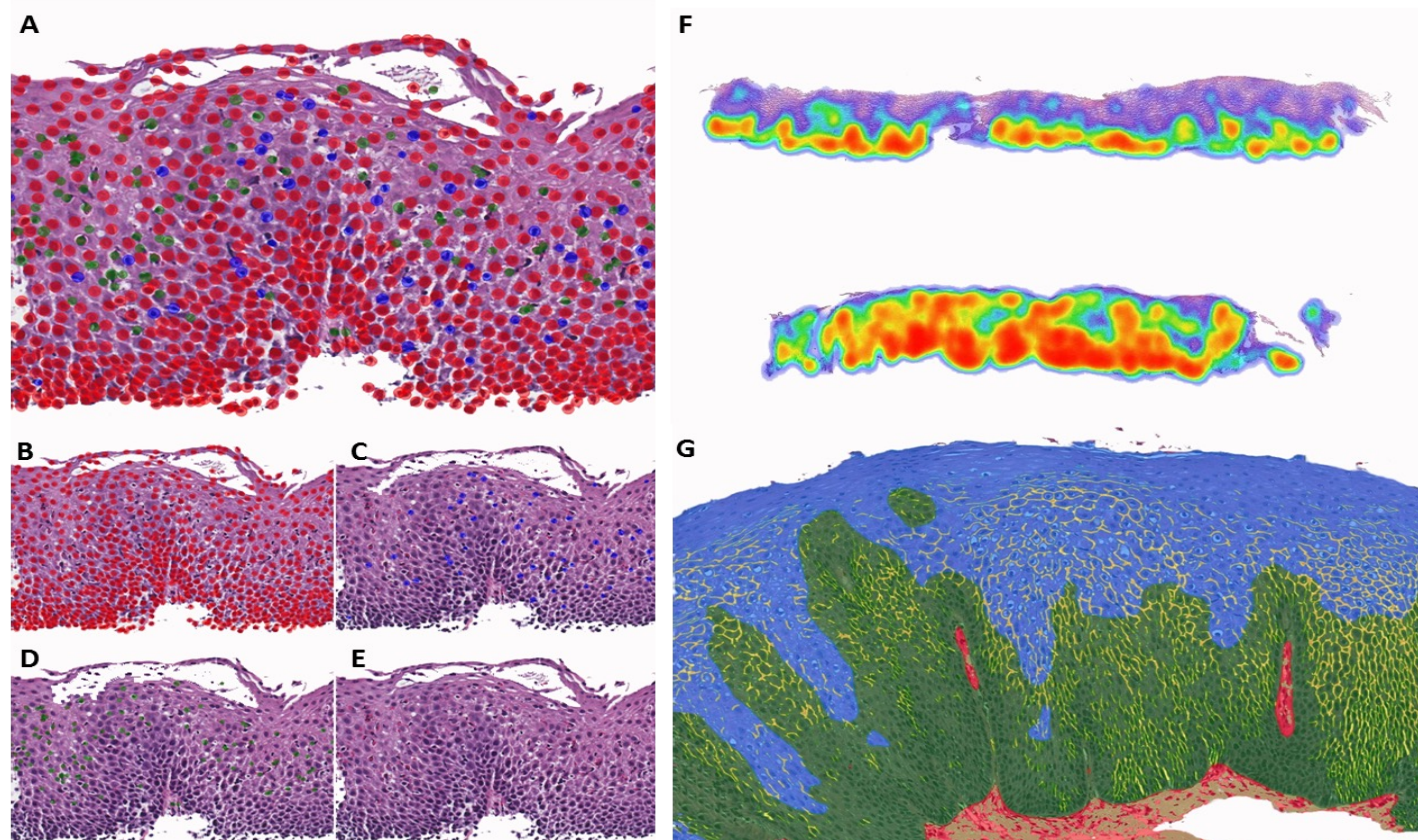


Figure 1. Cell recognition feature of our model. H&E stain with all cell types (A), squamous cell nuclei in red (B), lymphocytes in blue (C), eosinophils in green (D), and original H&E (E). Heat map showing distribution of cells of interest in a biopsy sample (F). Semantic segmentation features: mature/surface layer (blue), basal layer (green), spongiosis/dilated intercellular spaces (yellow), lamina propria (red), and collagen (light green).

## CONCLUSIONS

- Our newly developed AI-based tool showed an excellent performance (non-inferior to a group of experienced GI pathologists) for the recognition of various histologic features in the spectrum of EoE/esophageal mucosal eosinophilia.
- This tool represents an important step in creating an automated, accurate and reproducible method for quantitative analysis to be used in the evaluation of eosinophilic diseases of the esophagus.

## REFERENCES

1. Collins MH, et al. Newly developed and validated eosinophilic esophagitis histology scoring system and evidence that it outperforms peak eosinophil count for disease diagnosis and monitoring. *Dis Esophagus*. 2017;30(3): 1-8.
2. Warners MJ, et al. Reliability of histologic assessment in patients with eosinophilic oesophagitis. *Aliment Pharmacol Ther*. 2018;47(7):940-950.